

# Assessment of Mucosal Fibrosis and its Correlation with Disease Severity and Outcome in Cats with Chronic Enteropathy using Dual-Mode Emission and Transmission Microscopy

Evan Cosgrove<sup>1</sup>, Paula Giarretta<sup>2</sup>, Farzad Fereidouni<sup>3</sup>, Richard Levenson<sup>3</sup>, Valérie Freiche<sup>4</sup>, Sina Marsilio<sup>1</sup>

<sup>1</sup>UC Davis School of Veterinary Medicine, <sup>2</sup>Texas A&M College of Veterinary Medicine & Biological Sciences, <sup>3</sup>UC Davis School of Medicine, <sup>4</sup>National Veterinary School of Alfort, Paris, France

## Introduction

Chronic enteropathy (CE) is a common disease in older cats, comprising mainly of lymphoplasmacytic enteritis (LPE) and low-grade intestinal T cell lymphoma (LGITL). In people with inflammatory bowel disease fibrosis has been shown to correlate to severity of mucosal injury and inflammation. Fibrosis has also been a component of the World Small Animal Veterinary Association (WSAVA) guidelines for diagnosing gastrointestinal inflammation. However, its importance has only recently been investigated. A recent publication in cats with CE showed the location of mucosal fibrosis to directly correspond to a diagnosis of either LPE or LGITL.

The current gold standard for the histopathological assessment of fibrotic tissue in formalin-fixed biopsy specimens is trichrome staining. Several trichrome staining methods have been described in the literature, all of which require the processing and staining of a separate biopsy slide, a process that is elaborate, time- and resource consuming. A recent publication described a novel microscopy method termed Dual-Mode Emission and Transmission (DUET) that can be used to extract signals from regular H&E images that would typically require special stains or advanced optical methods. The technique allows the creation of virtual histochemical images that resemble trichrome-stained slides.

## Aims and Hypotheses

**Aim 1:** To assess mucosal fibrosis and correlate it to disease severity and outcome

-We hypothesized that fibrosis is underdiagnosed in cats with chronic enteropathy (CE) and is directly correlated with clinical signs, underlying diagnosis and patient outcome

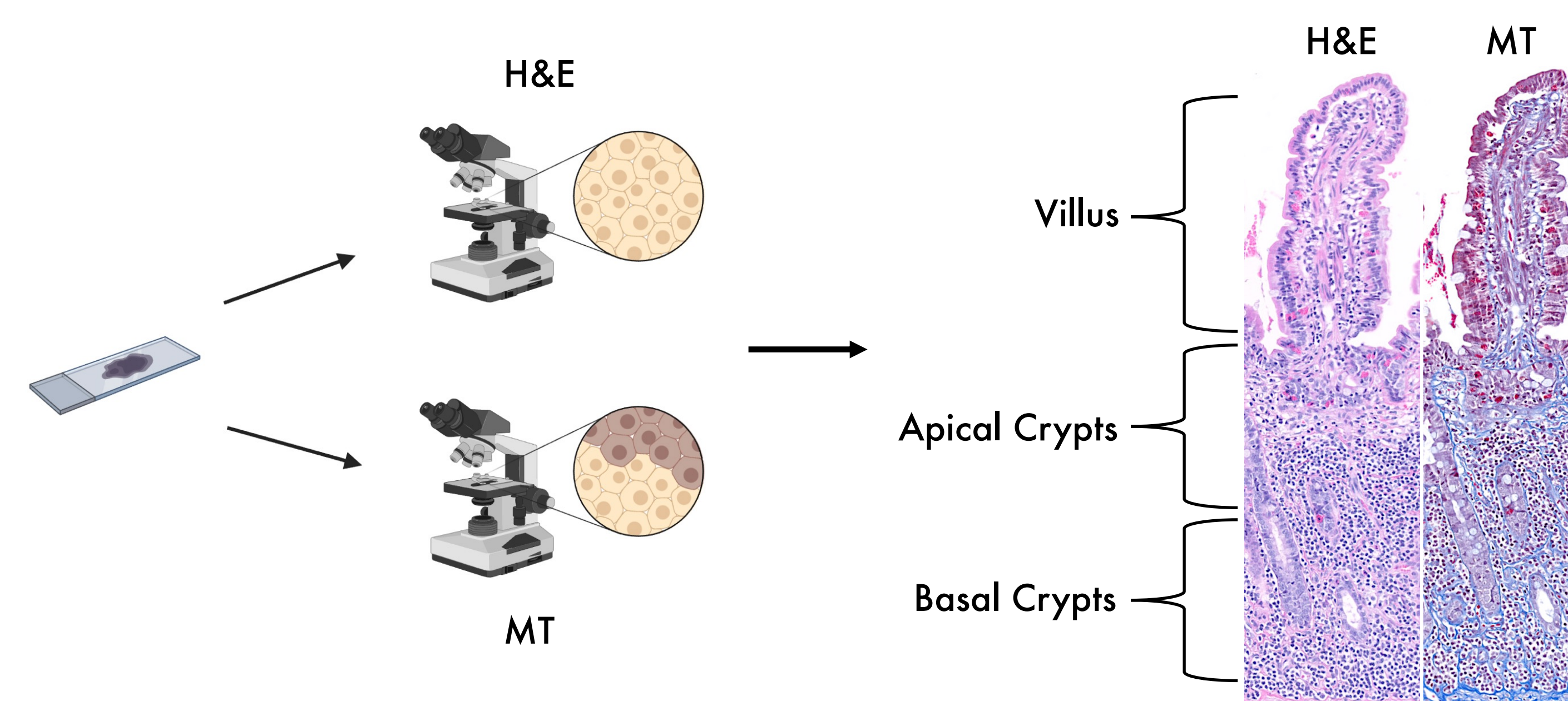
**Aim 2:** To compare DUET to Masson's Trichrome

-We hypothesized that DUET microscopy is equal to Masson's trichrome stain to evaluate mucosal fibrosis in cats with CE

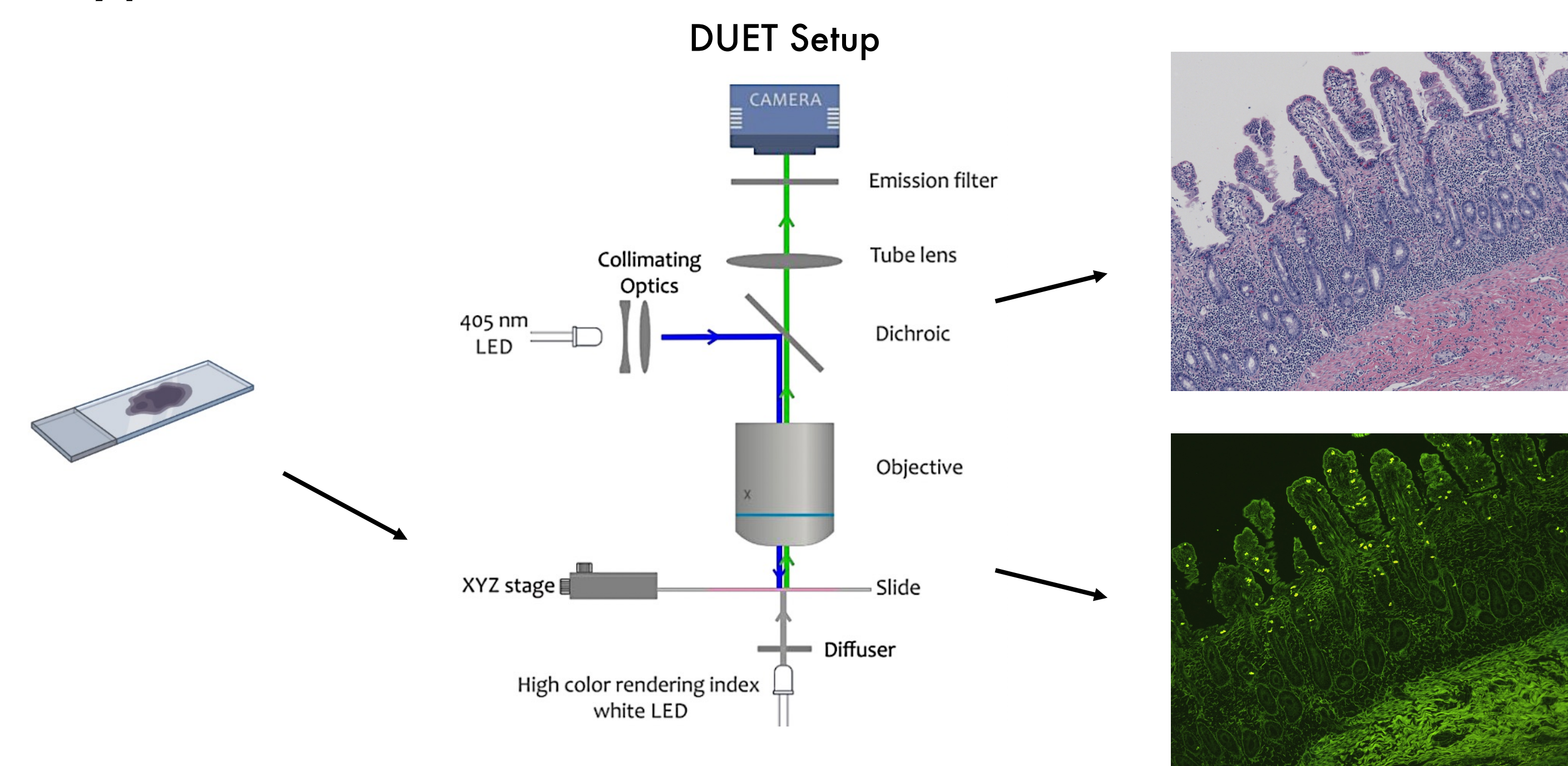
## Methods

**Aim 1:** Semiquantitative assessment of mucosal fibrosis (0-10% normal, 10-30% mild, 30-50% moderate, >50% severe) in 3 mucosal areas (villus, apical and basal crypt) → compared to WSAVA and clinical score)

## Methods (cont.)



**Aim 2:** Quantitative measurement of mucosal fibrosis and comparison of conventional MT stain to DUET based on the fractional collagen area in 3 regions (villus, apical and basal crypts)



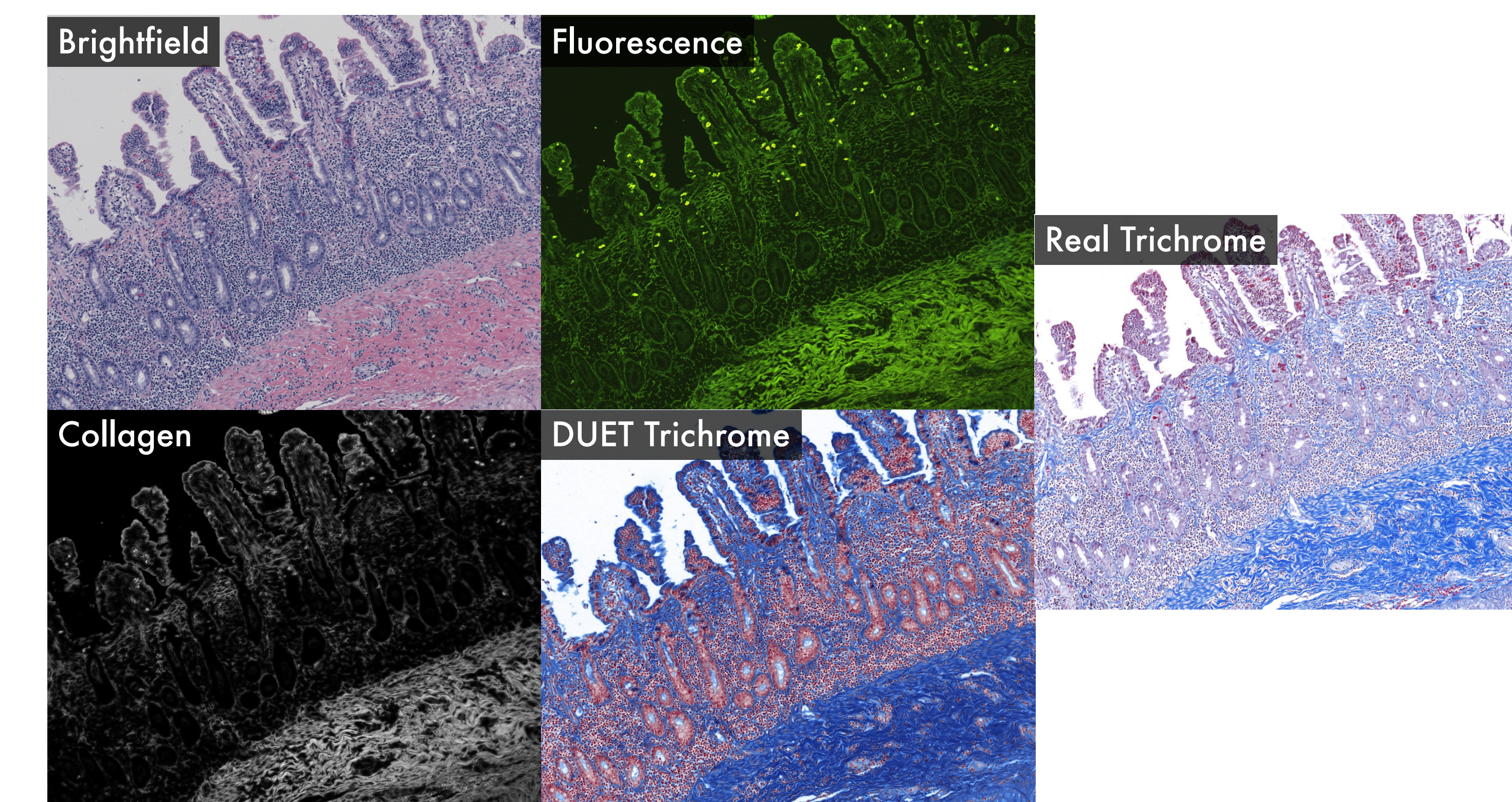
## Results

### Aim 1 (Preliminary Results)

- No significant difference in fibrosis between H&E and Masson's Trichrome
- No significant correlation between fibrosis score and WSAVA score
- No significant correlation between fibrosis score and clinical signs score

## Results (cont.)

### Aim 2



## Discussion

Based on our semi-quantitative assessment, we did not find fibrosis to be correlated to the WSAVA score or clinical score. However, more information, including a quantitative assessment for both aims is required before final conclusions can be made.

## Future Directions

Future studies should investigate a higher number of samples and create a more sensitive scale for the semi-quantitative assessment of fibrosis.

## Acknowledgments

I would like to thank all of our collaborators for their contributions and the STAR program for providing financial support through an endowment in the SVM. Some figures made using BioRender.com.

## References →

