

# Mechanical Validation of a Temporomandibular Joint (TMJ) Prosthesis for Companion Animals

Morgan Weed<sup>1</sup>, Boaz Arzi<sup>1</sup>, Denis J. Marcellin-Little<sup>1</sup>, Tanya Garcia-Nolen<sup>1</sup>

<sup>1</sup>Department of Veterinary Surgical & Radiological Sciences, School of Veterinary Medicine, University of California, Davis

## INTRODUCTION

TMJ ankylosis is fibrous or bony fusion of the joints connecting the lower jaws to the skull.<sup>1,2</sup> The cause of this disorder is usually idiopathic or secondary to maxillofacial trauma, infection, or unknown disease. The fusion of the TMJ presents as a rapidly progressive inability to open the mouth and oral problems from dental malocclusion. Secondary entrapment and swelling of the tongue from this disorder could lead to death.<sup>2</sup> Because of these symptoms, TMJ ankylosis is a severe and life-limiting issue leading to affected patients not being able to eat, drink, pant, and groom.

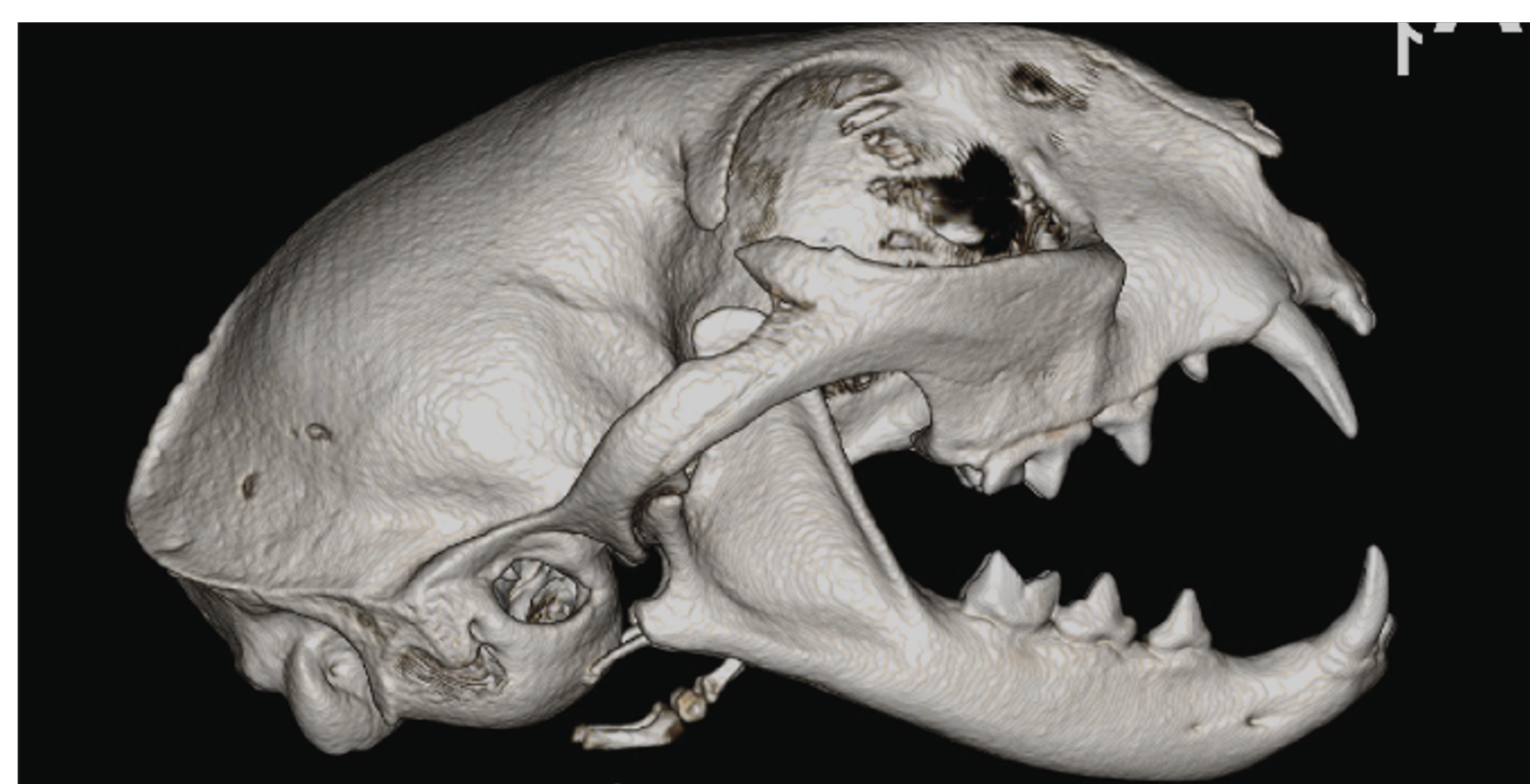

Figure 1. A three-dimensional reconstruction of a CT scan of a cat with a normal TMJ. Image courtesy of Dr. Arzi

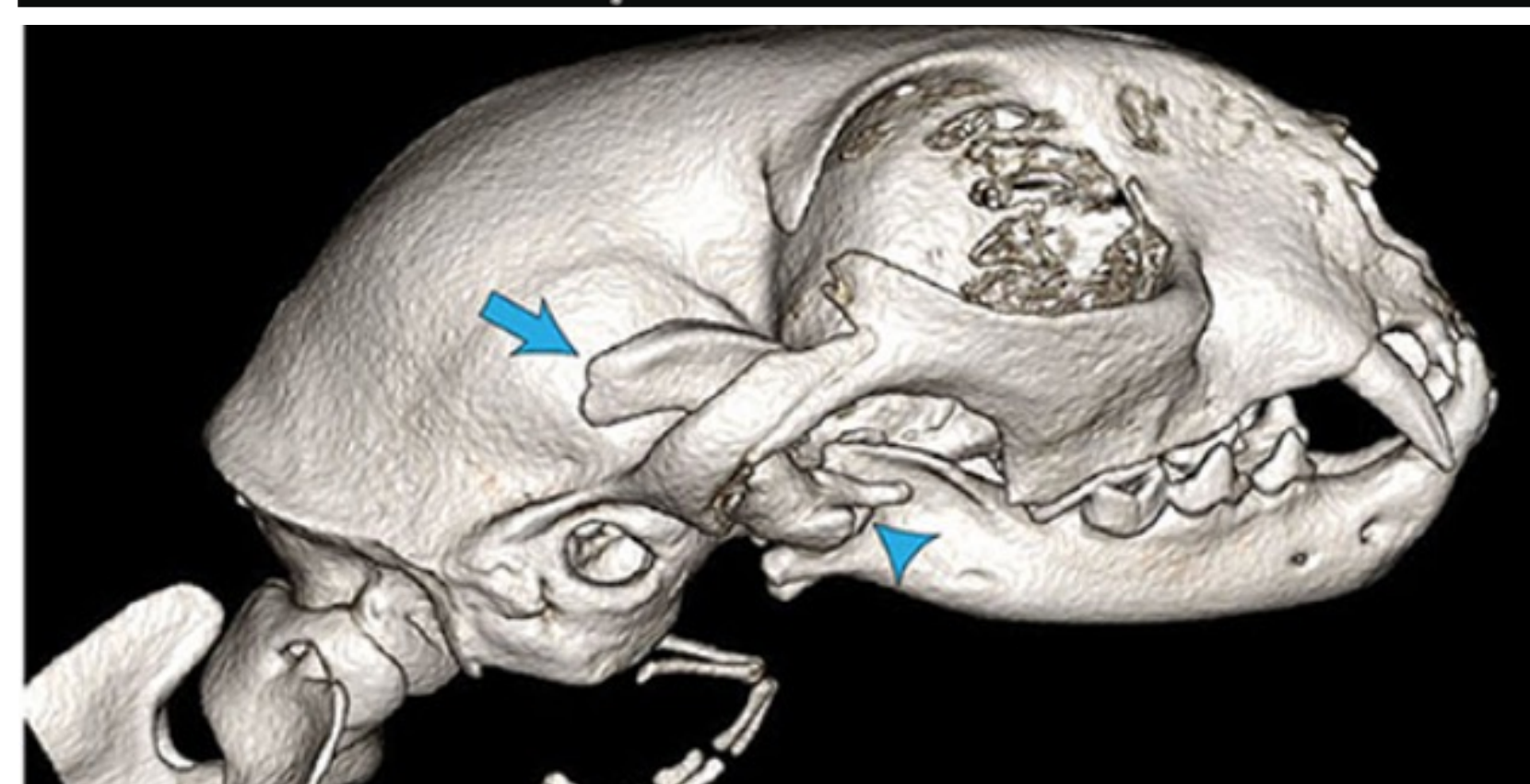


Figure 2. A three-dimensional reconstruction of a CT scan of a cat with TMJ ankylosis. Image courtesy of Dr. Arzi

The current treatment for TMJ ankylosis in dogs and cats is a salvage procedure called a gap arthroplasty. During this procedure, the extra bone growth (ankylosis tissue) is removed, including the entire TMJ.<sup>3</sup> This allows for mouth opening for fundamental needs of eating and drinking, but there are some significant drawbacks to this procedure. The patients will live the rest of their lives with unstable mandibles and the possibility of recurrence of the TMJ fusion.<sup>3</sup>

In human patients, however, the standard of care is a total temporomandibular joint replacement (TMJR) using a TMJR prosthesis.<sup>4</sup> This treatment option overcomes the consequences of a gap arthroplasty and returns the patient to normal function.<sup>5,6</sup> The goal is to be able to transition to a TMJR prosthesis as the standard of care for TMJ ankylosis in companion animals.

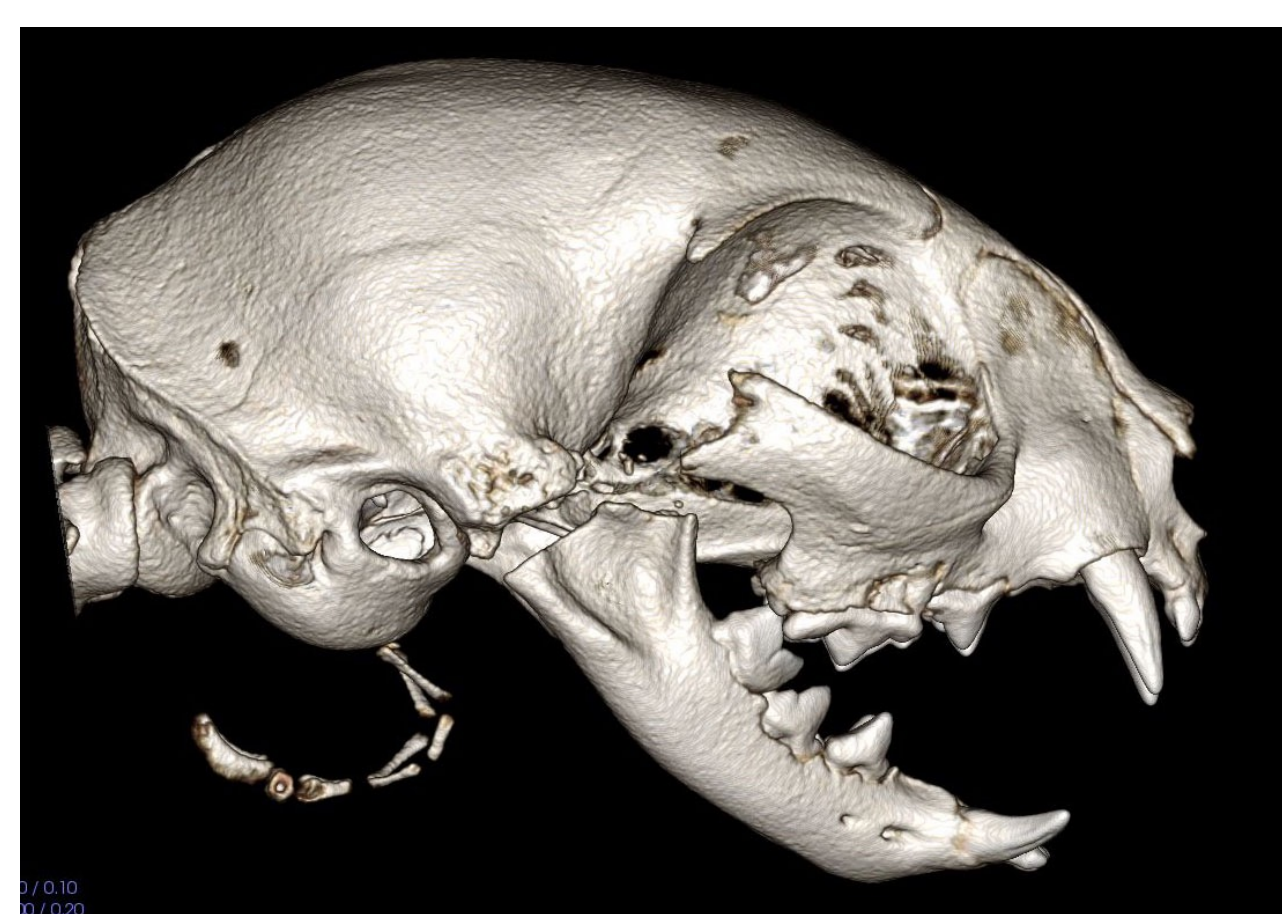

Figure 3. A three-dimensional reconstruction of a CT scan of a cat that underwent a gap arthroplasty to treat TMJ ankylosis. Image courtesy of Dr. Arzi

## STUDY GOALS

This group designed the first of its kind TMJR prosthesis for canine and feline patients. Because this prosthesis is novel, it is unknown how it will perform during normal ranges of motion and bite forces. The goal of this project was to evaluate the motion of healthy canine and feline cadaver mandibles before and after the implantation of a novel companion animal TMJR prosthesis. We hypothesized that the mandibular motions in the sagittal, frontal, and transverse planes of intact TMJ and TMJR do not differ by more than 50%.

## METHODS

8 canine and 8 feline cadaver skulls donated from the VMTH necropsy service for unrestricted use were used in this study. All muscles of mastication were excised from the skulls (temporalis, masseter, medial and lateral pterygoids, and the digastricus), while the TMJ was left intact. Hardware was placed to simulate muscle attachments to generate a mechanical muscle pull. Custom load cell holders were placed between the teeth to measure bite force.

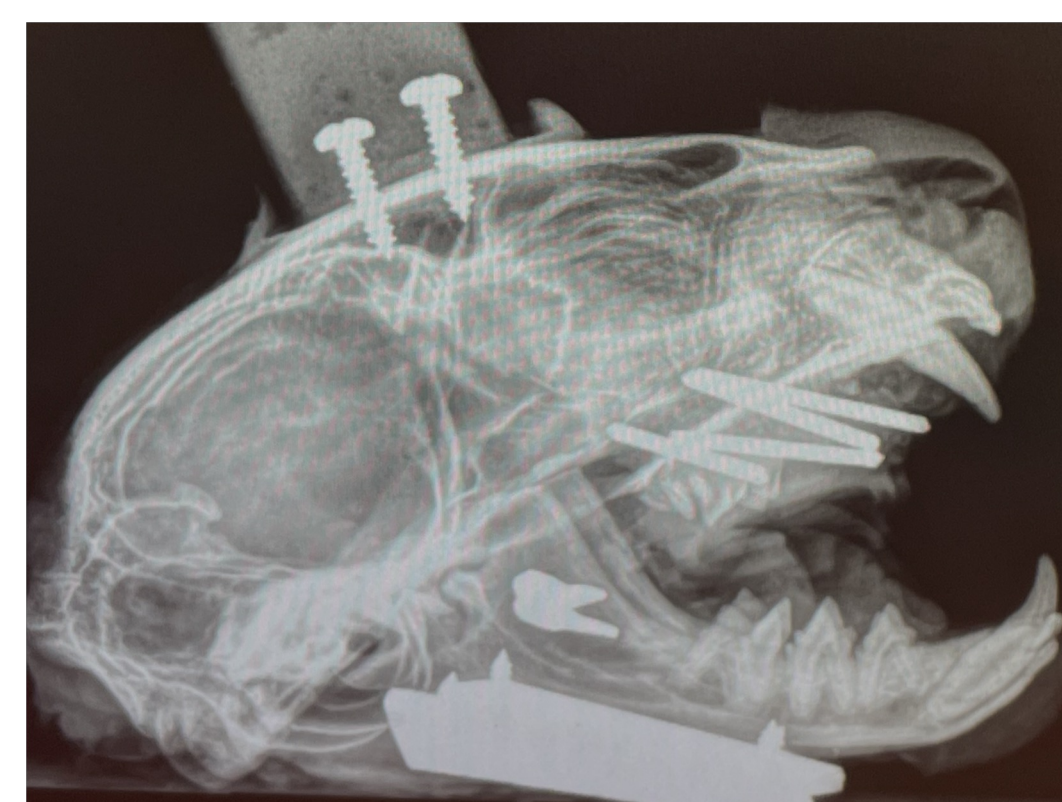

Figure 4. Radiograph of a feline skull with hardware placed for biomechanical testing.

The skulls were fixed onto a custom load frame with the mandible hanging freely. Mechanical muscle pulls were simulated using braided fishing line and pulley systems. The pulley system led to a mechanical lever with weight to simulate the force applied through the skull for a bite. A similar setup was used to simulate the digastricus muscle action of mouth opening.

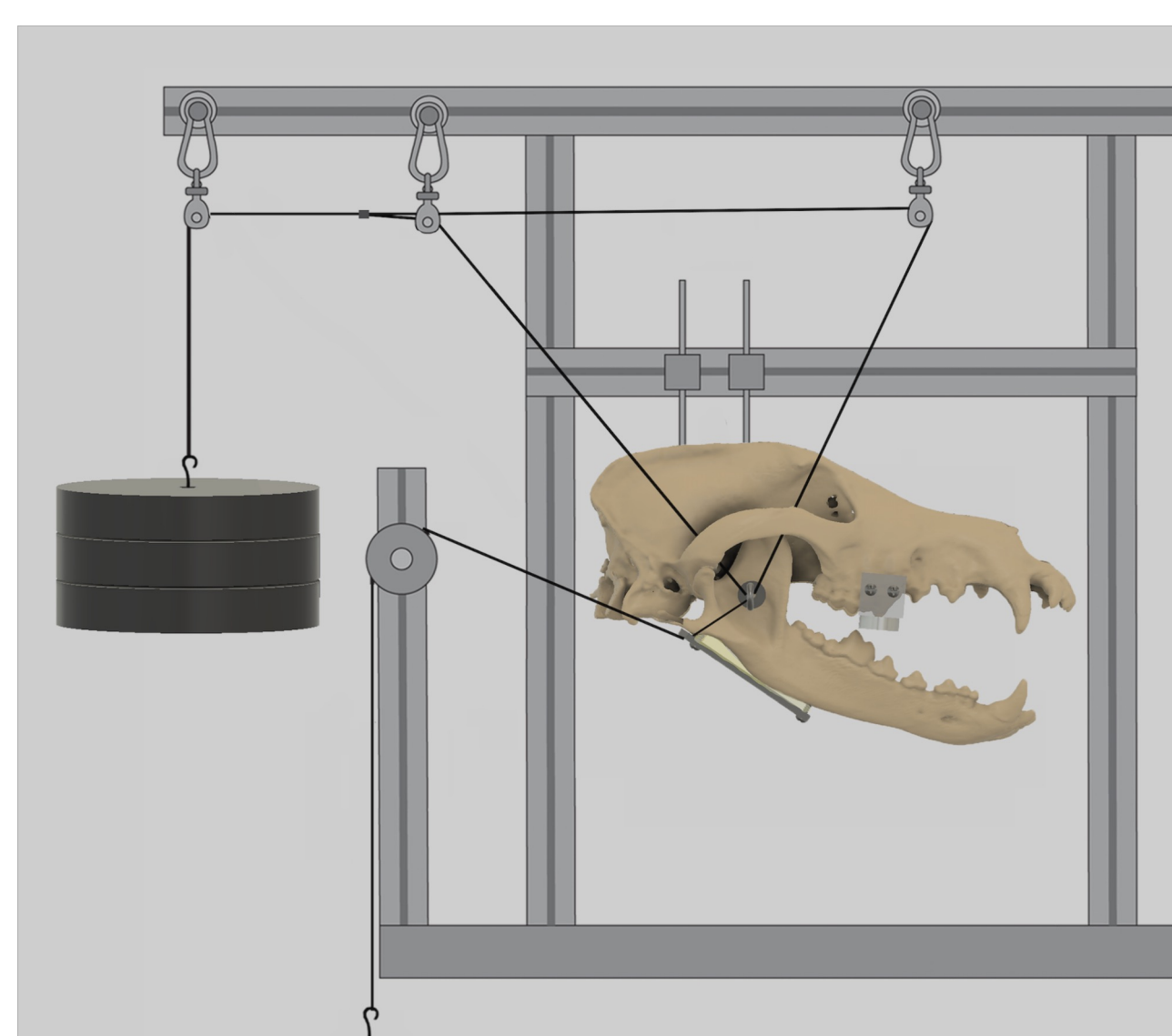


Figure 5. A three-dimensional schematic version of the biomechanical setup of the study with a canine skull. Image courtesy of Tanya Garcia-Nolen

We tested the displacements of the mandibles under 3 different conditions.

- Intact TMJ
- Unilateral TMJR prosthesis
- Bilateral TMJR prostheses

For each condition, we collected displacement data during a left bite, a right bite, and mouth opening. Data were collected and evaluated using digital image correlation (DIC) by Dantec Dynamics Inc. The displacements were recorded in the x, y, and z-planes for 3 regions of interest.

- Zygomatic arch
- Middle of the lateral aspect of the mandible
- Rostral point near the left mandibular canine tooth

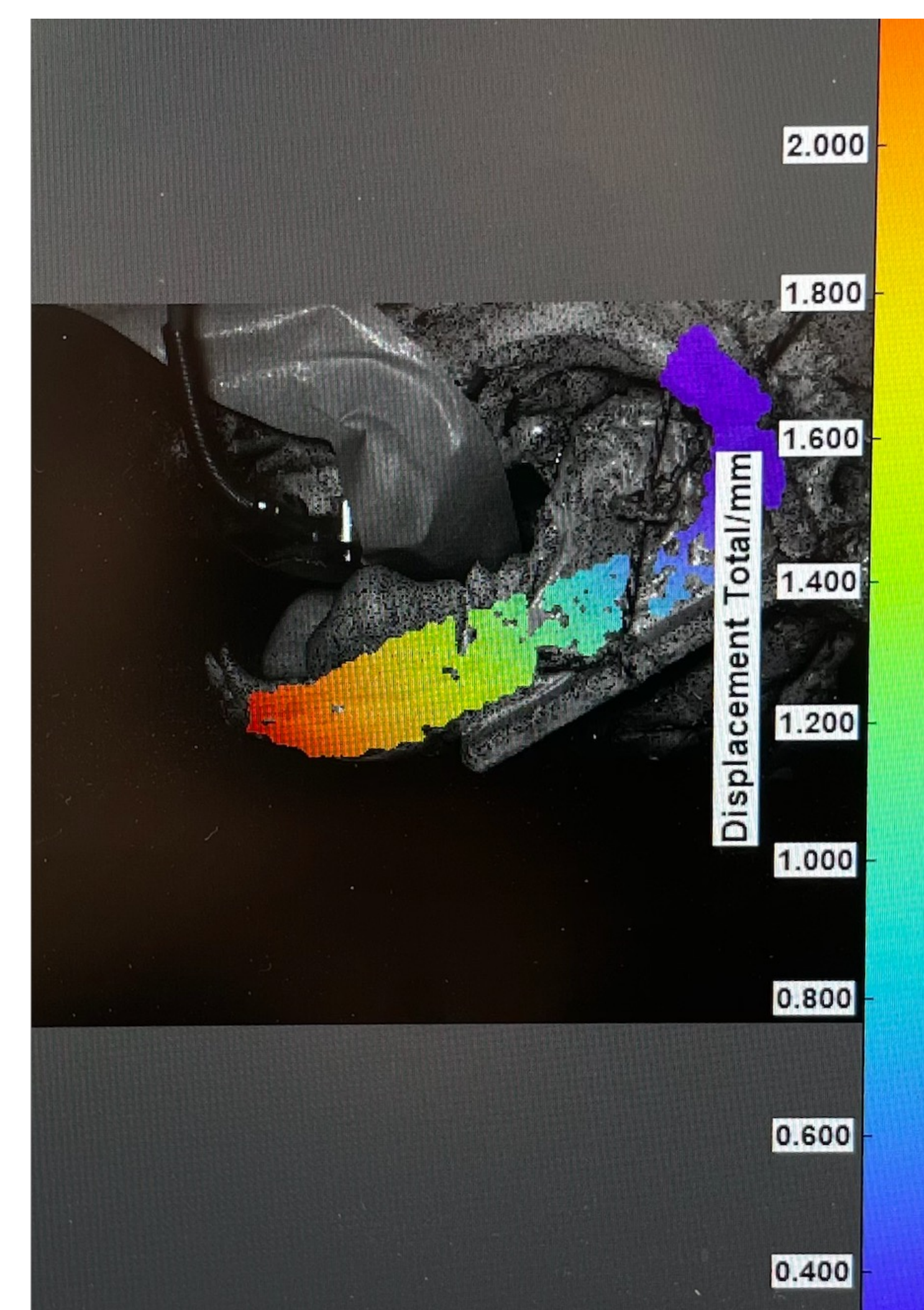


Figure 6. DIC data collection of mandibular displacement during a left bite on a feline skull.

## FUTURE DIRECTIONS

This project includes the first experiments in a series of tests validating the short-term and long-term performance of a novel TMJR prosthesis for companion animals. Specifically, additional mechanical validation of the TMJR prosthesis will be performed, including evaluating the stiffness and ultimate strength of prosthesis fixation, implant fatigue, and liner wear. Results from this project and the future validations will be used to inform potential design modifications to components of the novel TMJR prosthesis. This will be important to ensure the best long-term *in vivo* performance.

## ACKNOWLEDGEMENTS

This project was funded by the Students Training in Advanced Research (STAR) Program through the SVM Endowment Funds and the Center for Companion Animal Health (CDAH). A special thank you to the Veterinary Orthopedic Research Laboratory (VORL) for providing the tools and support to conduct this research project. A very big thank you to my mentors, Dr. Marcellin-Little, Dr. Arzi, and Tanya Garcia-Nolen for their continued guidance, instruction, and support throughout this project.



## REFERENCES

1. Strom PC, Arzi B, Cissell DD, et al. Ankylosis and pseudoankylosis of the temporomandibular joint in 10 dogs (1993-2015). *Vet Comp Orthop Traumatol* 2016; 29: 409-415.
2. Zavodovskaya R, Vapniarsky N, Garcia T, et al. Intra- and extra-articular features of temporomandibular joint ankylosis in the cat (*Felis catus*). *J Comp Pathol* 2020; 175: 39-48.
3. Aghashani A, Verstraete FJM, Arzi B. Temporomandibular joint gap arthroplasty in cats. *Front Vet Sci* 2020; 7: 482.
4. Tanaka E, Detamore MS, Mercuri LG. Degenerative disorders of the temporomandibular joint: etiology, diagnosis, and treatment. *J Dent Res* 2008; 87: 296-307.
5. Mercuri LG. *Temporomandibular joint total joint replacement – TMJ TJR: A comprehensive reference for researchers, material scientists, and surgeons*. Switzerland: Springer International Publishing, 2016.
6. Petty W. *Total joint replacement*. Philadelphia: W.B. Saunders, 1991.