



# Cardiac extracellular matrix remodeling in horses with cardiac pathology



**Cardiac extracellular matrix remodeling in horses with cardiac pathology**  
Jennifer R. Colangelo, Francisco A. Uzal, L. Joshua T. Morgan, Jessica M. Morgan

California Animal Health and Food Safety Lab System, University of California - Riverside, Department of Biotechnology, University of California, Davis, School of Veterinary Medicine, Department of Medicine and Epidemiology



**Background and Rationale**

**Background**

- The equine industry is considered to be public eye. Unlike that of any other animal species, horses are raised for a variety of purposes and are often used in a wide range of activities.
- Cardiac disease is a leading cause of death in horses and is a significant cause of economic loss.
- Despite the importance of cardiac disease, there is a paucity of research on the underlying mechanisms of cardiac disease in horses.
- Therefore, the purpose of this study was to investigate the underlying mechanisms of cardiac disease in horses.

OPEN


**Methods**

**Equine 1: Cardiac Remodeling in Heart Failure**

The study population included 10 Quarter Horse and 10 Quarter Horse geldings. The horses were divided into two groups: 5 with cardiac pathology and 5 without cardiac pathology. All horses were subjected to a standardized exercise protocol. The horses were then subjected to a standardized protocol for cardiac remodeling. The horses were then subjected to a standardized protocol for cardiac remodeling.

**Equine 2: Cardiac Remodeling in Sudden Death**

The study population included 10 Quarter Horse and 10 Quarter Horse geldings. The horses were divided into two groups: 5 with cardiac pathology and 5 without cardiac pathology. All horses were subjected to a standardized exercise protocol. The horses were then subjected to a standardized protocol for cardiac remodeling. The horses were then subjected to a standardized protocol for cardiac remodeling.




OPEN

**Results: Cardiac Remodeling in Heart Failure Cases**


**Background: Cardiac Remodeling in Heart Failure**

Heart failure is a complex condition that is characterized by the inability of the heart to pump enough blood to meet the body's needs. This condition is often associated with cardiac remodeling, which is a process in which the heart undergoes structural and functional changes in response to increased pressure and volume overload.



OPEN

**Results: Cardiac Remodeling in Sudden Death Cases**



OPEN

**Hypotheses and Aims**

**Objectives**

1. Determine the expression of the major matrix proteins, TGF- $\beta$ 1 and  $\alpha$ 1(I), in the cardiac extracellular matrix of acute congestive heart failure.
2. Quantify the degree of fibrosis present in the cardiac extracellular matrix of acute congestive heart failure.

[ABSTRACT](#) [REFERENCES](#) [CONTACT AUTHOR](#) [GET POSTER](#)

Jennifer R. Colangelo, Francisco A. Uzal, Joshua T. Morgan, Jessica M. Morgan

University of California, Davis - School of Veterinary Medicine Department of Medicine and Epidemiology, California Animal Health and Food Safety Lab System, University of California - Riverside, Department of Bioengineering



PRESENTED AT:



## BACKGROUND AND RATIONALE

### Background:

- The equine industry is constantly in the public eye. Sudden death of race horses during exercise raises animal welfare concerns and paints the industry in a negative light.
- 12% of racing fatalities between 2000 and 2009 were attributed to sudden death in the UK (256 out of 1981 deaths) and 9% in California (58 out of 659 deaths). (4)
- Despite undergoing post-mortem examinations, a substantial number of equine sudden death cases (47-69%) a definitive cause of death is not identified (5)
- Heart failure associated with a fatal arrhythmia is suspected in many of these cases, however there is a lack of definitive evidence to support this presumption.

### Rationale:

- Due to the lack of gross lesions on necropsy in many of these cases and the correlation between microscopic lesions and cardiac pathology in other species (9), it was logical to investigate microscopic changes to the cardiac extracellular matrix of these horses.
  - These changes include levels of fibrosis and expression of the extracellular matrix proteins Tenascin - C and Osteopontin.

### Tenascin-C and Osteopontin:

- Both Tenascin-C and Osteopontin are large matricellular proteins that help make up the extracellular matrix of the heart
- Investigating these two specific proteins will help understand the pathogenesis in cardiac sudden events in equine patients?
- Tenascin-C:
  - Upregulated during inflammation
  - Marker of acute injury (8)
- Osteopontin:
  - Upregulated during fibrosis/cellular repair
  - Marker for chronic injury/repair (6)

## HYPOTHESES AND AIMS

### Hypotheses:

1. Horses that succumb to heart failure have evidence of remodeling in the myocardium. This remodeling will include increased fibrosis and accumulation of matricellular proteins associated with remodeling of the extracellular matrix (Tenascin-C and Osteopontin).
2. Race-horses that experience exercise associated sudden death have evidence of remodeling in the myocardium. This remodeling will include increased fibrosis and accumulation of matricellular proteins associated with remodeling of the extracellular matrix (Tenascin-C and Osteopontin).

### Aims:

1. Evaluate the expression of the matricellular proteins Tenascin-C and Osteopontin in the cardiac extracellular matrix of cases compared to controls
2. Quantify the degree of fibrosis present in the cardiac extracellular matrix of cases compared to controls

## METHODS

### Hypothesis 1 - Cardiac Remodeling in Heart Failure:

The study population included 4 Thoroughbreds and 6 Quarterhorses as well as 2 Paint horses. The 6 cases succumbed to heart failure and the 6 controls succumbed to non-cardiac related disease. All cases and their matching controls were within one year of each other in age and of the same breed. All individuals were between 7 months and 11 years with a mean age of 8.7 years

Cardiac samples were selected retrospectively from available paraffin sections. Available samples were taken from multiple locations within the heart, including both the left and right atrium as well as the left and right ventricle.

### Hypothesis 2 - Cardiac Remodeling in Sudden Death Cases:

The study population included 12 thoroughbreds, 6 cases that succumbed to exercise associated sudden death and 6 cases that succumbed to catastrophic musculoskeletal injury on the race-track. Exercise associated sudden death is defined as sudden death within 60 minutes of exercise with no previously noted clinical signs and inconclusive post-mortem findings.

Samples were collected from the left atrium of equines that had died suddenly on the race track during exercise associated sudden death as described by Diab et al. (1). (Figure 1)

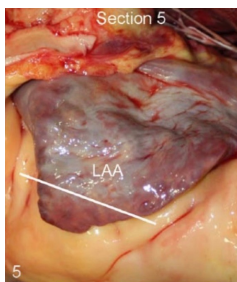


Figure 1

### Protein Expression Methods:

- Immunohistochemistry staining was utilized to evaluate the expression of Tenascin-C and Osteopontin in the myocardium.
  - The histology slides were deparaffinized and treated with a general IHC protocol
  - Tenascin: Human/Mouse Tenascin-C Antibody with a 1:50 dilution and detected with anti h/m Tenascin-C purified rat monoclonal IgG (R&D Systems Clone #578)
  - Osteopontin: OPN (AKm2AA1): sc-21742 and detected with OPN (AKm2A1) mouse monoclonal IgG

### Fibrosis Quantitation:

- Masson's Trichrome stained slides were used to evaluate the quantity of fibrosis present in the myocardium
- The quantitation of fibrosis using image analysis software (Matlab) is ongoing

In order to evaluate the protein expression within the myocardium as well as image the Masson's Trichrome slides, the stained slides were imaged using a Nikon Eclipse E600 Microscope and a Nikon DS Fi2 Camera as well as the NIS Elements Software

## RESULTS: CARDIAC REMODELING IN HEART FAILURE CASES

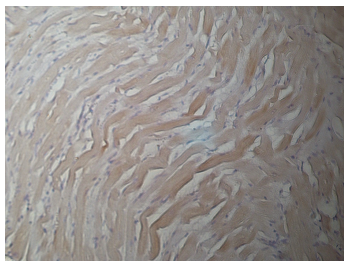
### Hypothesis 1 - Cardiac Remodeling in Heart Failure:

Increased Tenascin-C Expression in the myocardium of Heart Failure Cases compared to age and breed matched controls

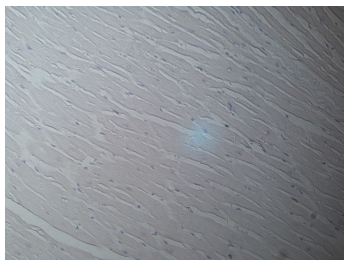
- Tenascin-C Expression is much higher in the heart failure cases compared to the controls

Osteopontin results pending

### Case:



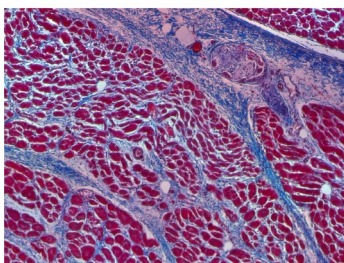
### Control:



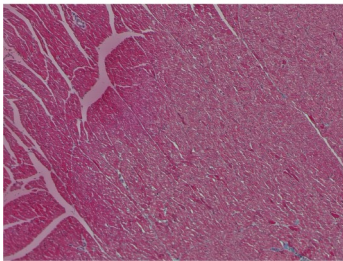
Increased levels of fibrosis in the myocardium of Heart Failure Cases compared to age and breed matched controls

- The quantity of fibrotic tissue is much greater in the heart failure cases when compared to the controls

### Case:



### Control:



## RESULTS: CARDIAC REMODELING IN SUDDEN DEATH CASES



### Preliminary Data:

Preliminary evaluation of cardiac histology from horses experiencing exercise associated sudden death (n=24) compared to controls experiencing musculoskeletal breakdown at the race-track (n=27). Revealed an increased prevalence of non-inflammatory myofiber injury (P=0.03, Fisher's Exact Test) in horses experiencing sudden death (16/24) compared to controls (9/27). Myofiber injury was most frequently observed in the left atrial appendage of sudden death horses (10/24) and never in the left atrial appendage of controls.

### Hypothesis 2 - Cardiac Remodeling in Sudden Death Cases:

Evaluation of Tenascin-C and Osteopontin expression as well as fibrosis quantitation in the race-horse population is ongoing. We hypothesize that similar increases in Tenascin-C expression and quantity of fibrosis will also be observed in the race-horse population.

## SIGNIFICANCE AND FUTURE RESEARCH

### Significance:

- The microscopic changes to the myocardium found in this study are the first steps to learning more regarding the pathogenesis of cardiac disease in horses.
- The data collected and evaluated in the course of this study will help determine the course of and chronicity of cardiac disease in equine patients.
- When the pathogenesis of these sudden cardiac events is better understood it is our hope that in the future, this information will direct treatment and diagnostic development pre-mortem.

### Future Research:

- Finish staining (immunohistochemistry) and imaging for protein expression and fibrosis quantitation
- Broaden the population
  - The more individuals that are a part of the study and the more data that can be analyzed, the greater the statistical significance of the results will be
- Protein and RNA quantitation using Western Blot and PCR
  - Will require fresh tissue samples



## ABSTRACT

Cardiac remodeling and its potential role in arrhythmogenesis contributing to sudden death is poorly understood in the horse. Histologic changes and changes in myocardial extracellular matrix are associated with heart failure and arrhythmogenesis in other species. This study aims to characterize changes to the myocardium in horses with cardiac diseases. It was hypothesized that horses that die of congestive heart failure and race-horses that experience exercise associated sudden death have evidence of remodeling in the myocardium compared to horses that died without evidence of cardiac disease. Evaluation of cardiac remodeling included histologic evaluation of the myocardium and specific staining for fibrosis and expression of matricellular proteins Tenascin C and Osteopontin. Remodeling was evaluated in histologic sections of myocardium from horses with heart failure (6) and age matched controls (6). Fibrosis was evaluated with Mason's Trichrome staining. Matricellular protein expression was evaluated with immunohistochemistry. Slides were evaluated both subjectively and objectively with automated image analysis (Matlab). Horses with cardiac disease showed increased regions of fibrosis and differential expression of matricellular protein tenascin C. These findings support the hypothesis that myocardial remodeling is associated with equine cardiac disease. Increased understanding of the role of remodeling in arrhythmogenesis make this a potential therapeutic target to reduce the incidence of sudden cardiac death in horses.

## REFERENCES

- (1) Diab, Santiago S. "Sudden death in racehorses: postmortem examination protocol." *Journal of Veterinary Diagnostic Investigation* (2017): 442-449.
- (2) Frangogiannis, Nikolaos G. "The Extracellular Matrix in Ischemic and Nonischemic Heart Failure." *Circulation Research* (2019): 117-146.
- (3) Gyongyosi, Mariann. "Myocardial fibrosis: biomedical research from bench to bedside." *European Journal of Heart Failure* (2016): 177-191.
- (4) Johnson, B., Ardans, A., Stover, S.M., Daft, B., Kinde, H., Read, D.H., Barr, B.C., Moore, J., Woods, L., Anderson, M., Stolz, J. and Blanchard, P. (1994a) California racehorse postmortem program: A 4-year overview. *Proc. Am. Ass. equine Practnrs.* 40, 167-169.
- (5) Lyle, C. H. "Sudden death in racing Thoroughbred horses: An international multicentre study of post mortem findings." *Equine Veterinary Journal* (2011): 324-331.
- (6) Miragliotta, V. "Osteopontin expression in healing wounds of horses and in human keloids." *Equine Veterinary Journal* (2014): 118-131.
- (7) Nath, L. "Myocardial Fibrosis is Present in Thoroughbred Racehorses with Sudden Cardiac Death." *Heart, Lung and Circulation* (2019): 219.
- (8) Nemoto, Manabu. "Tenascin-C Expression in Equine Tendon derived Cells During Proliferation and Migration." *Journal of Equine Science* (2013): 17-24.
- (9) Yoshida, Kyoko. "Tenascin-C in Heart Diseases - The Role of Inflammation." *International Journal of Molecular Sciences* (2021): 1-17.